

Rorschach Dermoscopy

Andreas Blum, MD; Giuseppe Argenziano, MD; Jonathan Bowling, MD; Jason Giacomel, MBBS; Rainer Hofmann-Wellenhof, MD; Jurgen Kreuzsch, MD; Iris Zalaudek, MD; James Grichnik, MD; Public, Private, and Teaching Practice of Dermatology, Konstanz, Germany (Dr Blum); Dermatology & Skin Cancer Unit, Arcispedale Santa Maria Nuova IRCCS, Reggio Emilia, Italy (Dr Argenziano); Oxford University Hospitals NHS Trust, Oxford, United Kingdom (Dr Bowling); Mends St Medical Centre, South Perth, Western Australia (Dr Giacomel); Medical University of Graz, Graz, Austria (Drs Hofmann-Wellenhof and Zalaudek); Public and Private Practice of Dermatology, Lübeck, Germany (Dr Kreuzsch); and Miller School of Medicine, University of Miami, Miami, Florida (Dr Grichnik)

AS DERMATOLOGISTS, WE RECOGNIZE THE patterns of skin disease. Dermoscopy allows us to visualize even finer lesion detail. It is generally used to increase diagnostic accuracy, but sometimes the pattern may conjure a secondary, abstract meaning. We present

6 dermoscopic cases that will test your Rorschach dermoscopy skills (**Figures 1, 2, 3, 4, 5, and 6**).

Financial Disclosure: Dr Grichnik is a shareholder and founder of Digital Derm Inc, has served as a consultant to Genentech Inc, and has received equipment and meeting support from Lucid Inc.

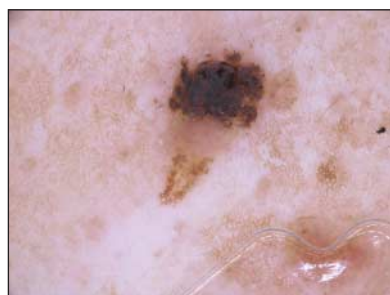


Figure 1. Double-scoop ice-cream cone or a seborrheic keratosis?

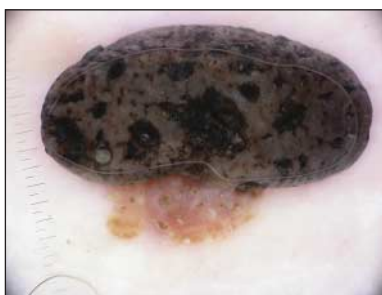

Figure 2. Rain cloud, mushroom, or a seborrheic keratosis?

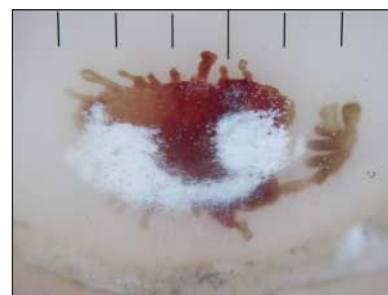

Figure 3. Ostrich or a subungual hematoma with superficial white onychomycosis?

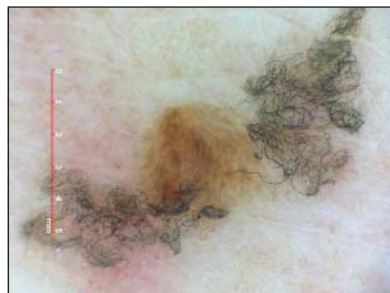


Figure 4. Flying bat or sock lint and seborrheic keratosis?

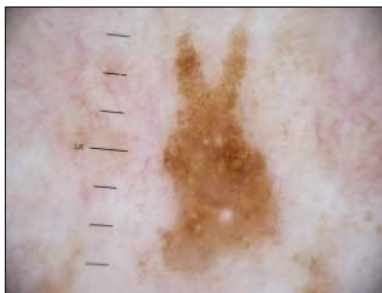

Figure 5. Easter bunny or a seborrheic keratosis?

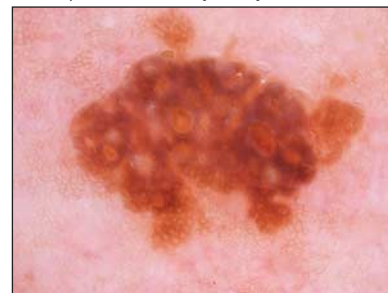


Figure 6. Turtle, dromedary, or a seborrheic keratosis?

EDITOR'S NOTE

Farewell to skINsight

Since the first publication of skINsight in July 2003, Dr Grichnik and his assistant section editors, Drs Marghoob and Scope, have fine-tuned the submissions to this section, which has helped define many of the dermoscopic patterns. Over the years, more clinicians have become comfortable using dermoscopy because of the descriptions provided in skINsight. The editors and authors who have published original reports have helped transform the practice of dermatology by giving clinicians the guidance they need to feel comfortable incorporating dermoscopy into their evaluation of lesions.

It is time to pause to recognize this transformation as well as to surmise that most of the novel features obtained by the use of dermoscopy have been defined. It was good to begin well in 2003. It is better to end well in 2012 with the final skINsight. Farewell and thank you to all who helped make skINsight a success.

June K. Robinson, MD
Editor
Jeffrey P. Callen, MD
Associate Editor